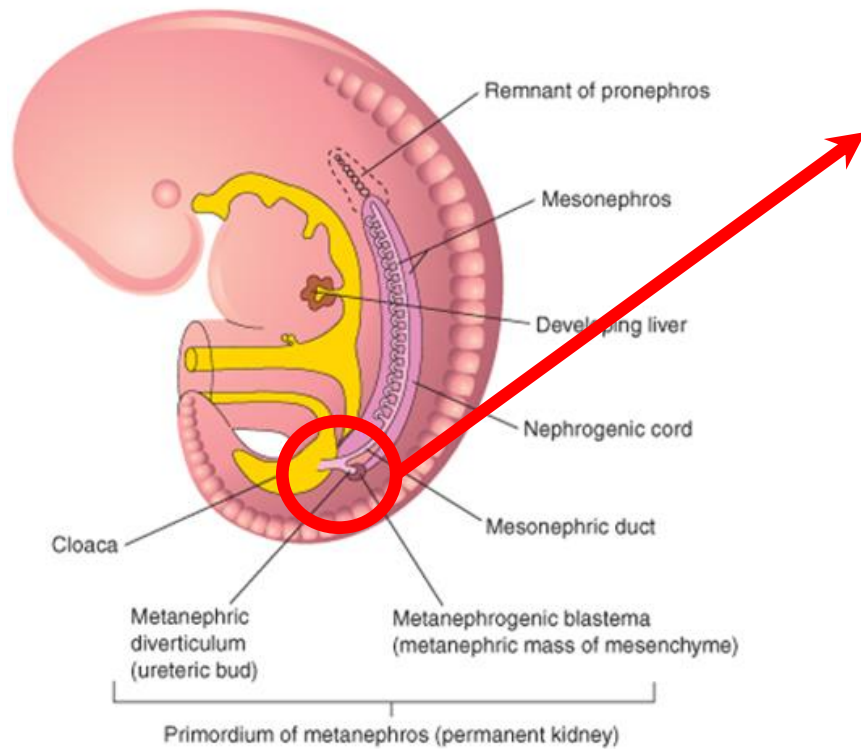


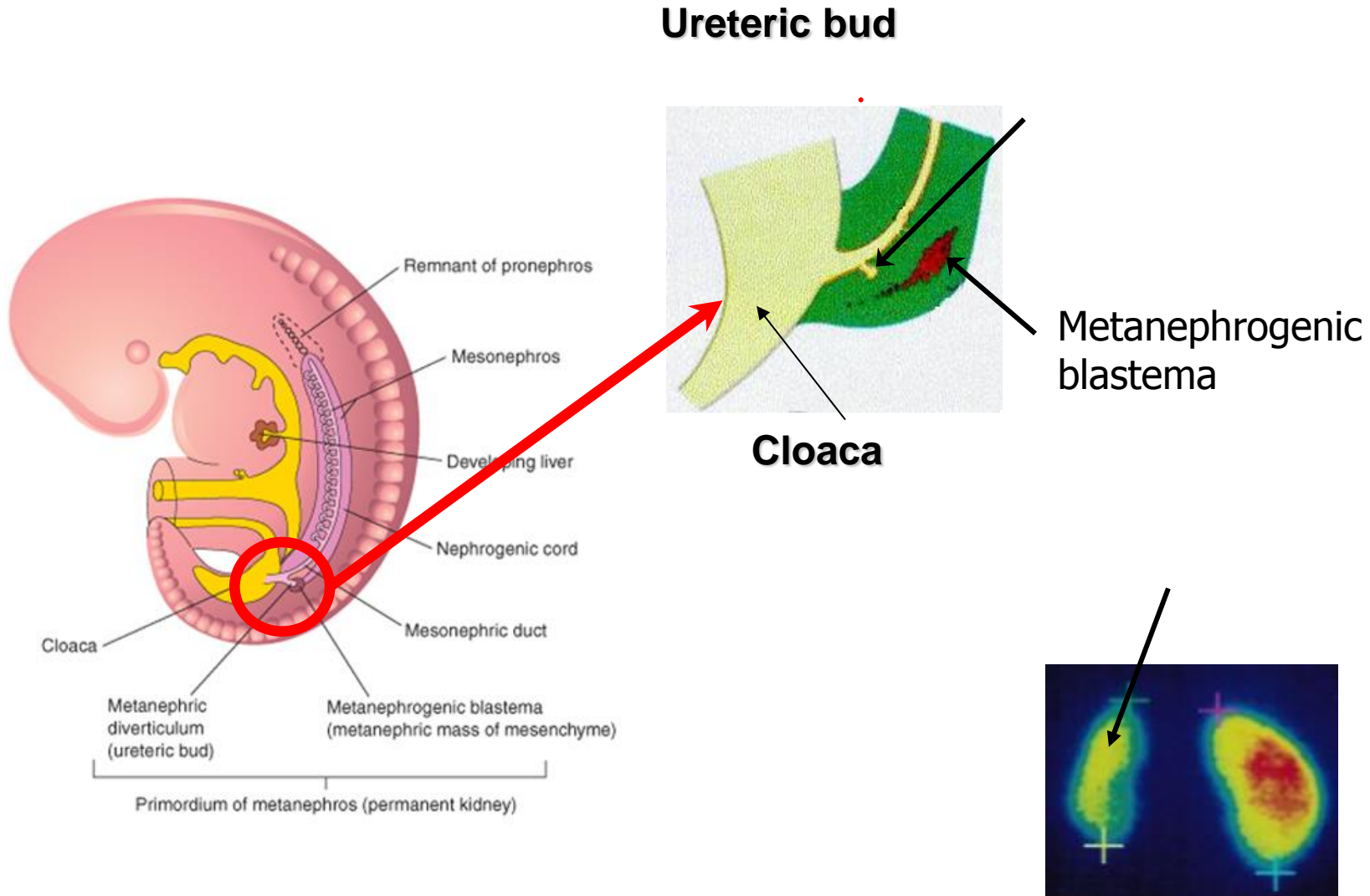
5th week of pregnancy

3 mm

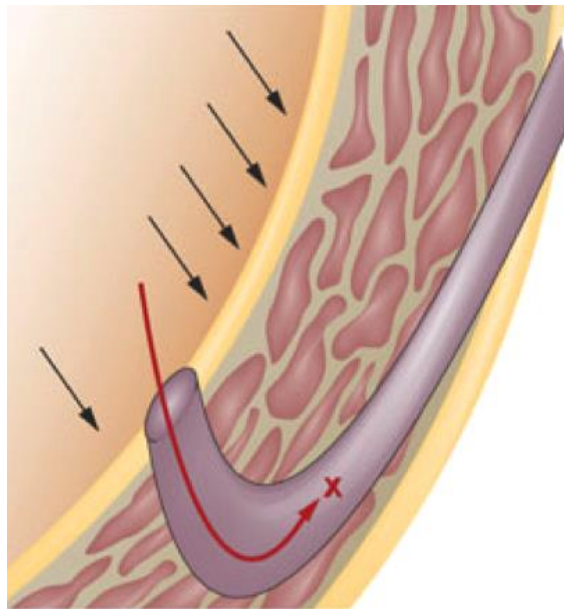
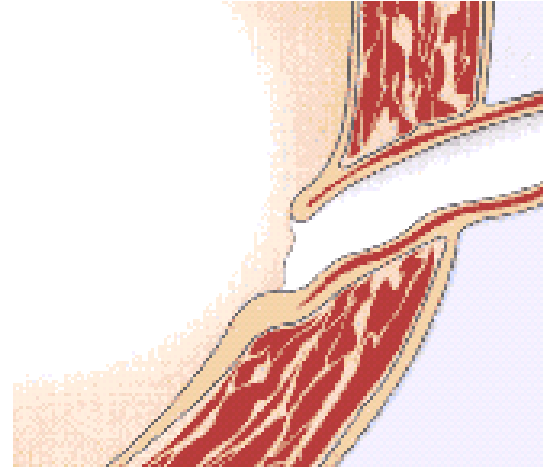
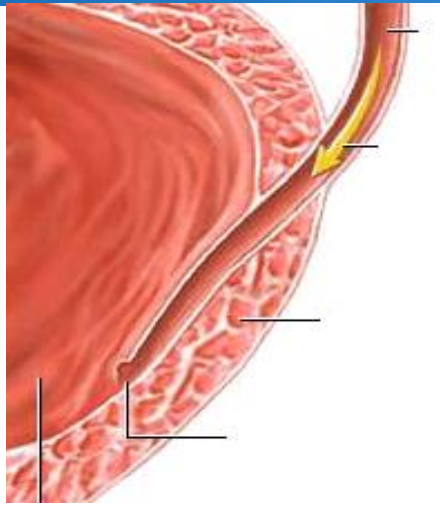


5th week of pregnancy

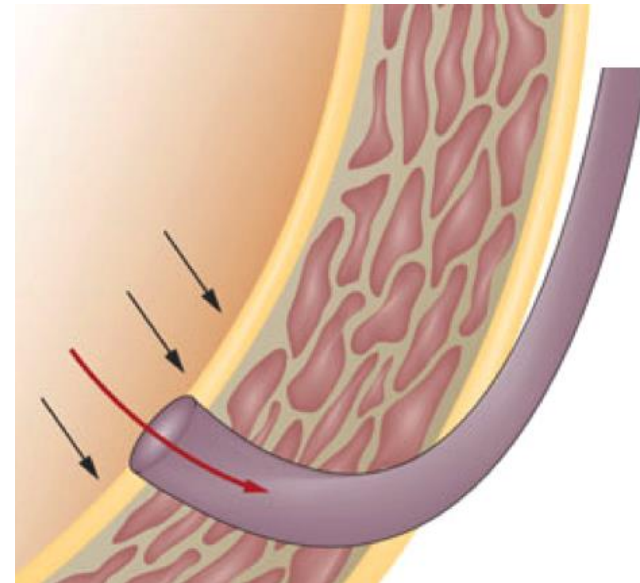
3 mm



Ureteric tunnel

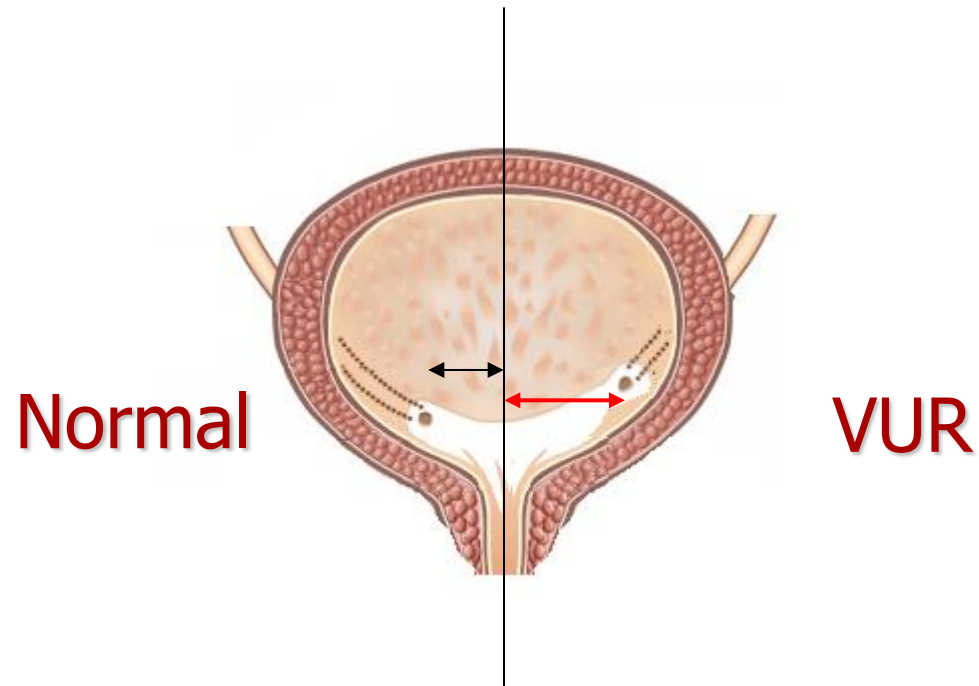
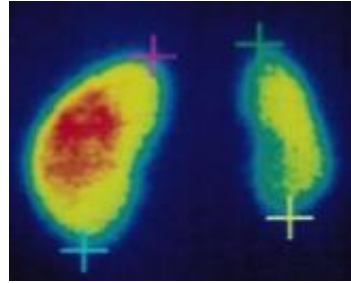


Normal



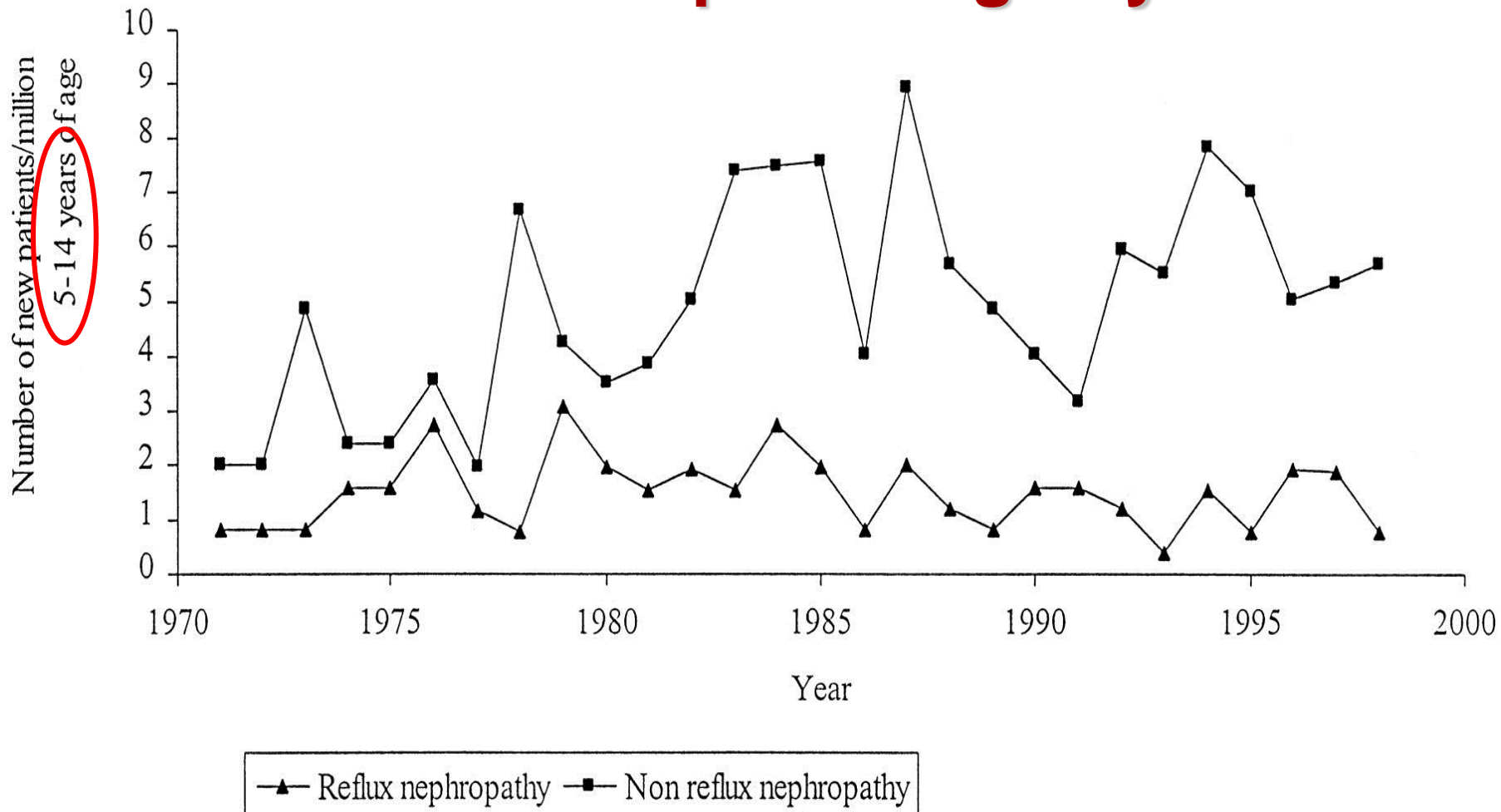
VUR

Ureteric tunnel



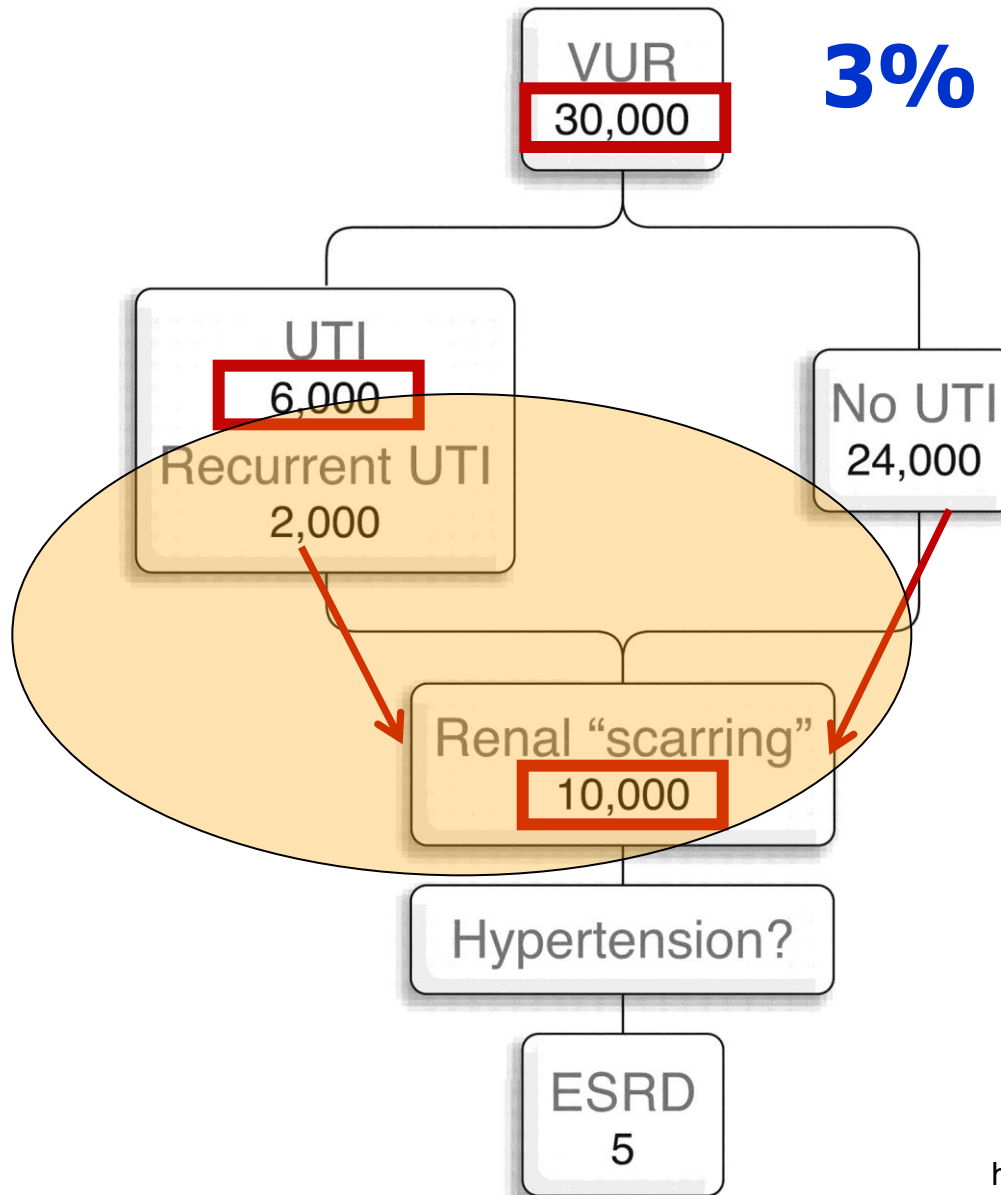
Mackie and Stephens (1975)

Australia and New Zealand Dialysis and Transplant Registry



Craig JC, Irwig LM, Knight JF, Roy LP: Does treatment of vesicoureteric reflux in childhood prevent end-stage renal disease attributable to reflux nephropathy? *Pediatrics* 2000,105:1236-1241.

Conceptual model for 1 million of children



McIlroy PJ et al.
J Paediatr Child Health 36 : 569 –573, 2000

<http://jasn.asnjournals.org/cgi/content/full/19/5/847>

PREDICT study

Antibiotic Prophylaxis and Renal Damage In Congenital Abnormalities of the Kidney and Urinary Tract (PREDICT)

G Montini et al